



**Society of Radiologists in Ultrasound  
2012 Toshiba Residents Program**

John Kim, M.D.  
Mentor: Monzer Abu-Yousef, M.D.  
University of Iowa Hospitals & Clinics

**Clinical History:**

36-year-old man incarcerated for drunk driving. He was found to have a right scrotal mass on routine physical exam. Scrotal ultrasound exam with color Doppler was then performed which showed the following

**Figures:**

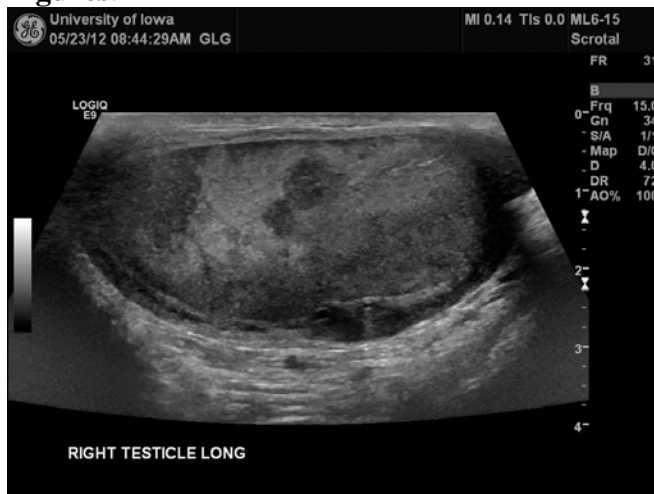

Figure 1A: Grayscale ultrasound images of the right testis showing multiple hypoechoic areas suspicious for malignancy.

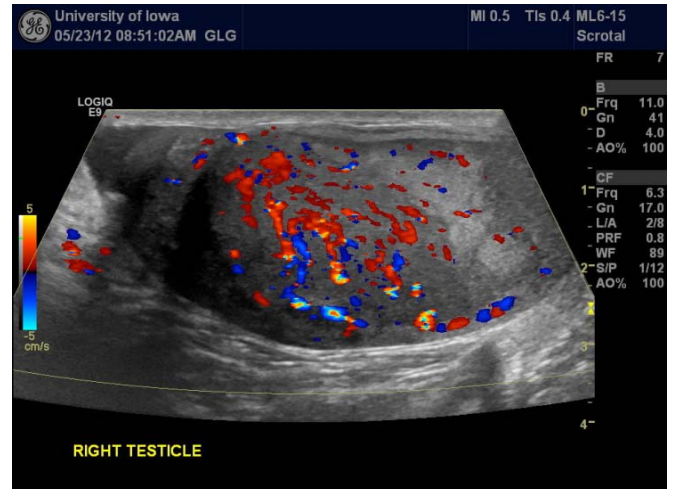
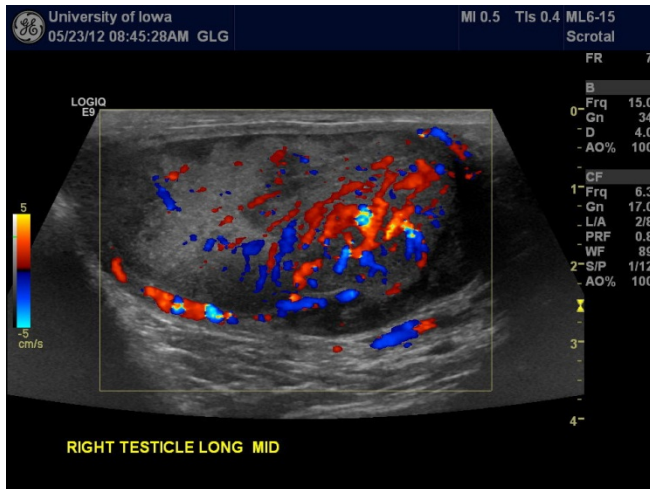


Figure 1B: Color Doppler exam of the right testis shows hypervascularity especially in the hypochoic regions, which is highly suspicious for malignancy, but infection is not excluded.

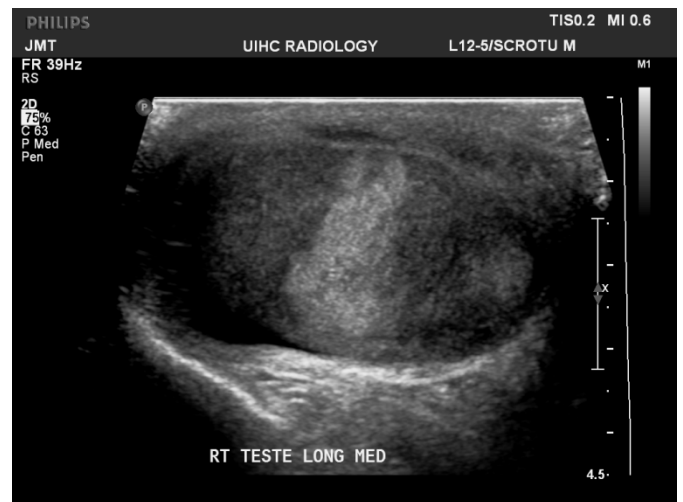
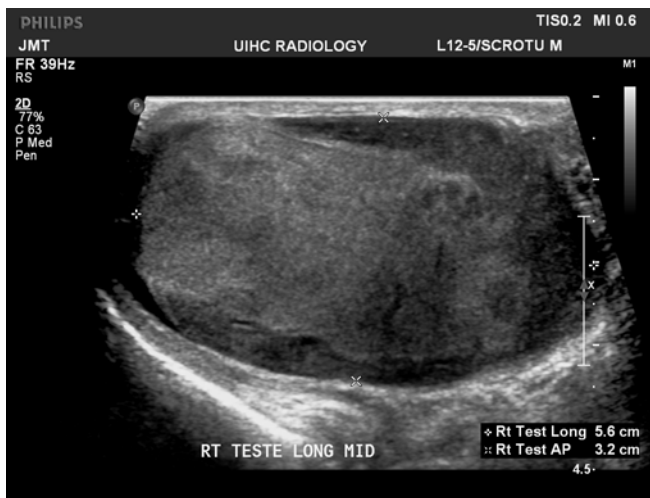
Figure 2A: Repeat ultrasound exam with color Doppler done 3.5 months later continues to show multiple hypochoic areas. The right testis also appears larger, more heterogeneous and rounded in shape suggestive of an enlarging mass.

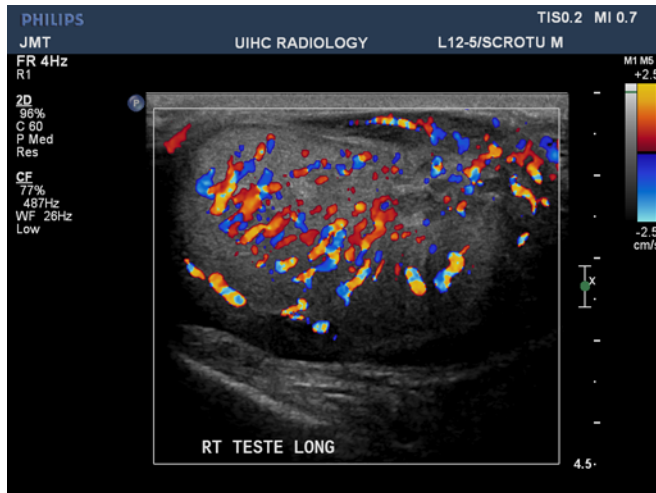


Figure 2B: Increased vascularity on color Doppler of right testis.

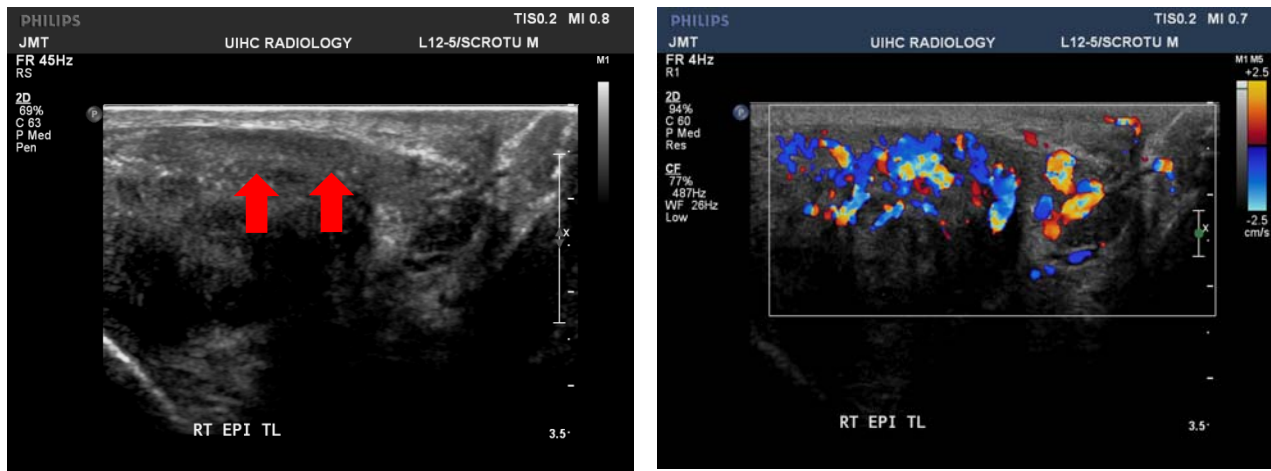


Figure 2C: Grayscale and color Doppler of the right epididymis shows enlargement (red arrows) and hypervascularity.

**Diagnosis:**

Diffuse large B-cell lymphoma, of the right testicle germinal center type

**Discussion:**

Testicular involvement by lymphoma or leukemia is usually to secondary involvement elsewhere in the body. Testicular lymphoma accounts for 1% to 9% of all testicular tumors [1]. It is the most common secondary neoplasm of the testis and the most common testicular malignancy in men older than 60 years [2]. It most often presents as a painless scrotal mass which can be

bilateral. Therefore, testicular lymphoma should be considered the highest on the differential in anyone with known history of lymphoma or leukemia who presents with a scrotal mass.

Grayscale and color Doppler ultrasound findings include diffuse testicular infiltration/enlargement with hypervascularity or multifocal areas of hypoechoic, solid, and hypervascular nodules within the testes [3]. It may sometimes demonstrate involvement and enlargement of the epididymis with increased flow [4]. Hypervascularity of the testes and epididymides may also be found in lymphoma/leukemic infiltration and epididymo-orchitis and differentiating them based on ultrasound can be challenging [4,5]. It is important to correctly distinguish between diffuse lymphoma/leukemic testicular infiltration and epididymo-orchitis as the treatment is vastly different.

In our case, the patient did not have any significant past medical history or recent health issues, but a routine physical exam identified a right scrotal mass. The presence of round, hypoechoic solid nodules with hypervascularity (Figures 1A-1B) in the clinical setting of painless scrotal mass raised the suspicion of malignancy. Ultrasound of the left testis also demonstrated two small, nonpalpable but suspicious hypoechoic lesions. Despite the concern for malignancy, the patient initially refused further workup and definitive therapy. Three & ½ months later, the patient finally agreed to undergo surgical resection of the right testis and biopsy of the left testis. A repeat ultrasound at that time (Figures 2A-2C) showed testicular and likely right epididymal involvement with stable left testis findings. The right testis was pathologically proven to be diffuse large B-cell lymphoma, and the left testis hypoechoic lesions were proven to be benign hyalinized nodules.

#### References:

1. Shahab N, Doll D. Testicular lymphoma. *Semin Oncol* 1999; 26:259–269.
2. Ferry JA, Harris NL, Young RH, Coen J, Zeitman A, Scully RE. Malignant lymphoma of the testis, epididymis, and spermatic cord. *Am J Surg Path* 1994; 18:376-390
3. Bloom C, Hamilton P, Cassoff J, et al. Scrotal ultrasonography: a pictorial essay. *Can Assoc Radiol J* 1998;49:12.
4. Ishigami K, Yousef-Zahra DM, Abu-Yousef MM. Enlargement and Hypervascularity of Both the Epididymis and Testis Do Not Exclude Involvement with Lymphoma or Leukemia. *J. of Clinical Ultrasound*. 2004 32:365-369.
5. Middleton WD, Kurtz AB, Hertzberg BS. Lower Genitourinary. In: Thrall JH, (ed). *Ultrasound: The Requisites* 2nd Ed. St. Louis: Mosby, 2004: 152-190.

**Authors:**

Resident: John Kim, M.D.

Faculty: Monzer Abu-Yousef, M.D.

**Mentor:**

Monzer Abu-Yousef, M.D.

**Institution:**

University of Iowa Hospitals & Clinics

Department of Radiology

200 Hawkins Dr.

Iowa City, IA 52242