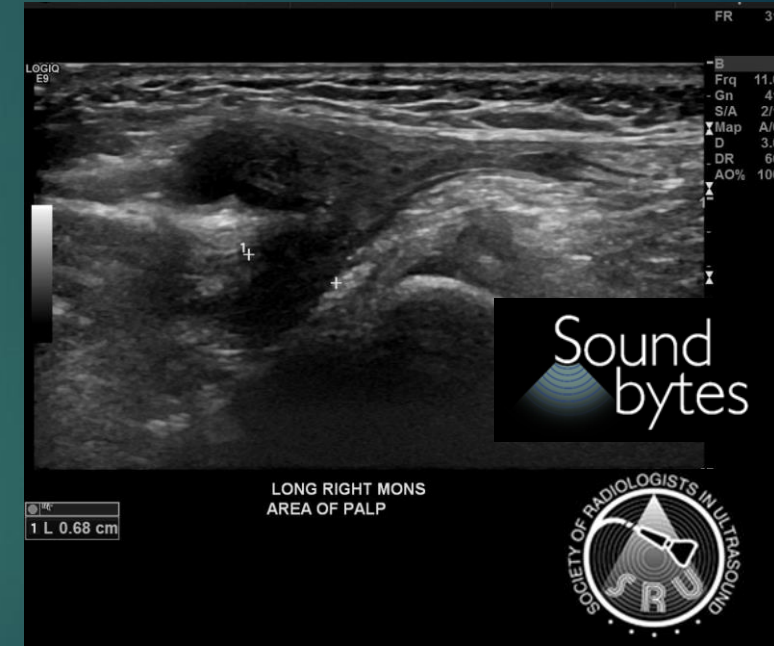
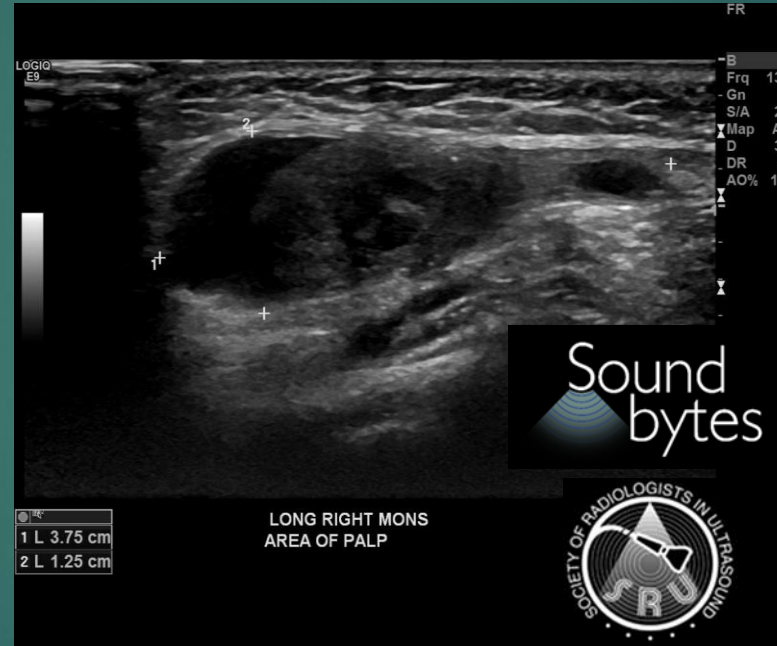
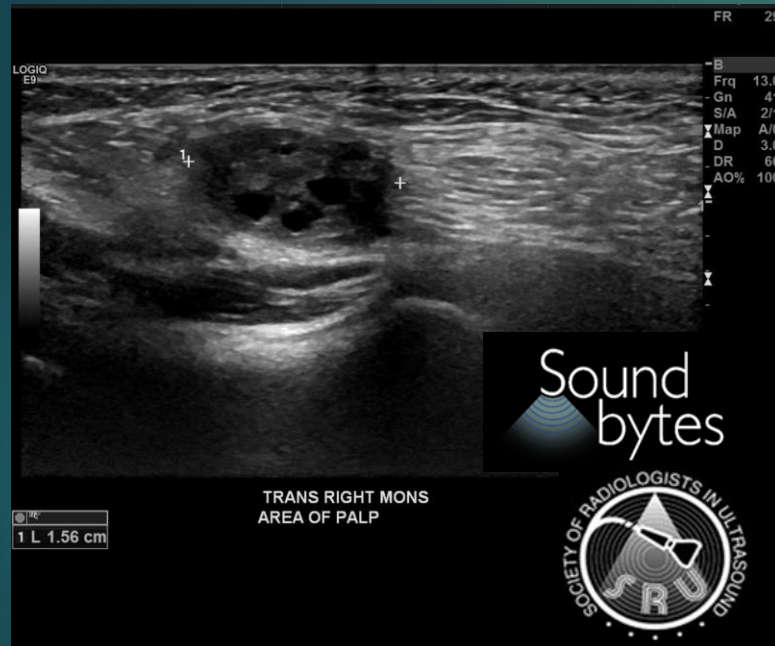




SRU Case of the Day 2023

Kelly Broderick M.D.
California Advanced Imaging Medical Associates

History: 9 month old female with swelling right mons pubis



Diagnosis: herniated right ovary in Canal of Nuck

- ▶ Failure of obliteration of inguinal canal
- ▶ Ovary, uterus, fallopian tube and bladder can herniate
- ▶ Surgically repaired due to high rate of torsion