

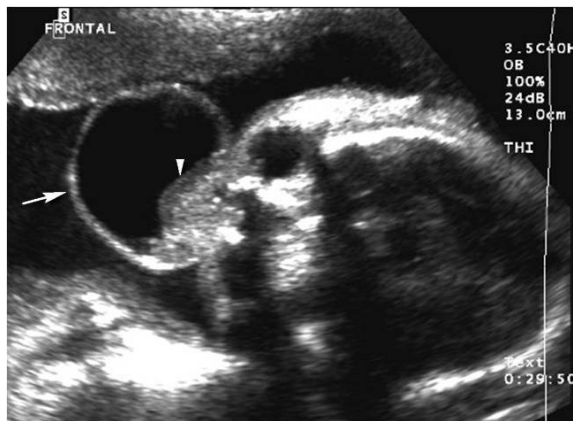


Patricia Sims Poole, MD  
University of California San Diego  
San Diego, CA

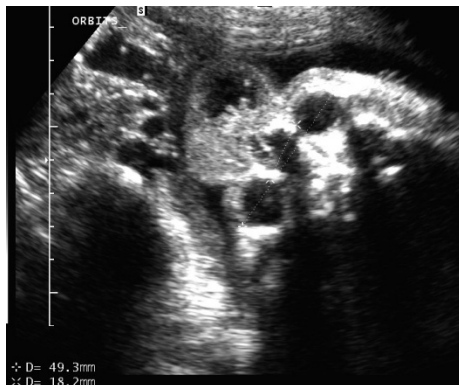### Clinical History

18 year old female presented for late care at 28 weeks gestation with no complaints.

### Figures and Legends

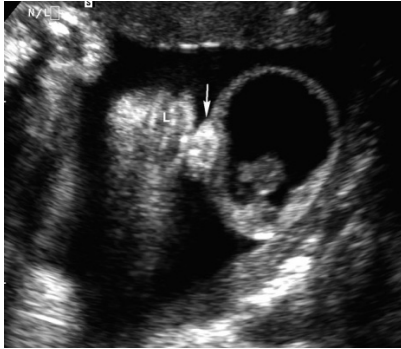

**Figure 1: Transabdominal axial image through the orbits demonstrates an enlarged anechoic structure extending from the root of the nose (arrow). Small amount of echogenic material is noted within the posterior aspect of the cystic lesion (arrowhead).**

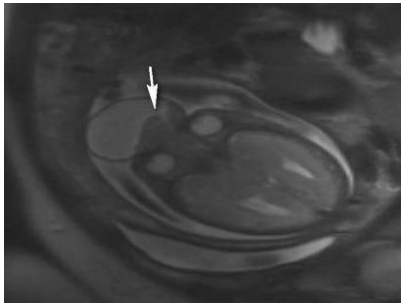


**Figure 2: Transabdominal axial image through the orbits and base of the nose demonstrates a midline cystic mass with internal echogenic material, which appears isoechoic to the adjacent brain**

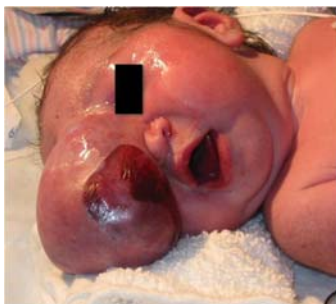parenchyma herniating into the prenasal space. Also note increased space between the orbits compatible with hypertelorism.



**Figure 3: Coronal transabdominal image through the nose (arrow) and lips (L). Note the well circumscribed cystic lesion superior to the nose with internal tissue, compatible with brain tissue herniating into a frontonasal encephalocele.**



**Figure 4: Axial HASTE MRI confirms the midline thin-walled, well circumscribed, primarily fluid density mass protruding through the frontal and nasal bones. The mass has an area of soft tissue density (arrow), which is isointense to the underlying brain parenchyma. Often brain tissue contained in an encephalocele is non-functioning and will appear hyperintense to the normal brain secondary to gliosis.**



**Figure 5: Gross image demonstrating the midline mass extending through the frontal and nasal bones, compatible with a large frontonasal encephalocele.**

## **Diagnosis**

Frontonasal Encephalocele

## **Follow-up**

Following a non-eventful cesarean delivery, our patient had MR imaging confirming a moderately large frontonasal encephalocele extending through the inferior forehead. There was associated left and probably right neuronal migrational disorder with cerebral dysplasia. The patient was taken to the operating room on day of life 10 with successful closure of the skull base frontonasal encephalocele.

## **Discussion**

An encephalocele is a defect in the skull and dura with extracranial extension of brain tissue and meninges. The overall incidence is approximately 0.2 per 1000 live births and fetal deaths [1,2]. Most encephaloceles are located in the midline and imaging demonstrates a defect in the skull with a cystic mass containing extracranial extension of brain tissue. On ultrasound this will appear as an anechoic or hypoechoic mass with a thin, well circumscribed wall. This mass can contain internal echogenicity compatible with herniating brain tissue. Often the herniated brain tissue is nonfunctioning, and therefore, the herniated tissue will appear isointense to brain on CT, iso- to hypointense on T1 weighted images and hyperintense on T2 weighted images secondary to gliosis.

Encephaloceles occur secondary to a disturbance in the separation of surface ectoderm and neuroectoderm during closure of the neural folds early in embryonic development. Sixty percent of encephaloceles are associated with other brain/cranial abnormalities including, spina bifida, corpus callosum dysgenesis/agenesis, Chiari malformation, Dandy-Walker malformation, migrational abnormalities, or chromosomal abnormalities like Trisomy 18 [2]. Therefore, it is crucial that a thorough evaluation of the remaining fetal anatomy is done to rule-out chromosomal abnormalities and syndromes.

The nomenclature of encephaloceles is based on the origin of their roof and floor. For instance, our patient had an anterior cranial fossa encephalocele with the frontal bone as the roof and the nasal bone as the floor, and is therefore termed a frontonasal encephalocele. Anterior cranial fossa encephaloceles can be subdivided into sincipital and basal encephaloceles.

Sincipital encephaloceles account for 13-15% of all encephaloceles [2], but are the most common variety in Southeast Asia, where they occur in 1 in 5000 births [3]. Sincipital encephaloceles include frontonasal (40-50%), nasoethmoidal (30%), and a combination of both (10%) [2]. Frontonasal encephaloceles demonstrate herniation of dura mater through the foramen cecum and fonticulus frontalis, whereas nasoethmoidal encephaloceles demonstrate herniation of dura through the foramen cecum into the prenasal space. Sincipital encephaloceles can present with an obvious midface mass and hypertelorism, like the patient in this case. CT can be useful for pre-operative planning and demonstrates a bifid or absent crista galli or absent cribiform plate/frontal bone. Unlike most occipital, parietal, or basal

encephaloceles, sincipital encephaloceles can be treated with complete surgical resection, as there is no normal function of the herniated brain tissue.

Basal encephaloceles account for 10% of all encephaloceles [2]. Basal encephaloceles include sphenopharyngeal, spheno-orbital, sphenoethmoidal, transethmoidal and sphenomaxillary encephaloceles. These are clinically occult and usually do not present until after the first decade of life. They can present with difficulty breathing or diminished visual acuity, or simply as a mass in the nasal cavity, nasopharynx, mouth, or posterior portion of the orbit. Eighty percent of patients with basal encephaloceles have agenesis of the corpus callosum.

Occipital encephaloceles are the most common encephalocele in the western hemisphere accounting for 75% of the total number of encephaloceles [2]. Occipital encephaloceles are associated with Meckel-Gruber syndrome (occipital encephalocele, microcephaly, cystic dysplastic kidneys, and polydactyly), Dandy-Walker malformation, and Chiari malformations [2]. Occipital encephaloceles can present with a skull defect in 80% of patients, flattening of the basiocciput, ventriculomegaly, the lemon sign, and an acute angle between the mass and the skin line of the neck/occiput [2].

Parietal encephaloceles account for 10-12% of all encephaloceles [2]. Parietal encephaloceles can demonstrate a hole in the sphenoid bone or a split cranium skull defect with a sclerotic rim of cortical bone. Parietal encephaloceles are associated with dysgenesis of the corpus callosum, large interhemispheric cysts, hydrocephalus, or microcephaly.

The treatment of encephaloceles varies based on their location and the surrounding vital structures. Therefore, if an encephalocele is detected, it is important to obtain imaging to look for the location of major vascular structures in relation to the defect. If there is normal appearing herniated brain tissue, it can sometimes be restored into the intracranial compartment. However, usually the tissue is dysplastic, and therefore resected. After resection of the herniated material or replacement of the herniated material into the intracranial cavity, the dura mater is closed in a watertight fashion and any craniofacial skeletal abnormalities are reconstructed. The most common postoperative complications include CSF leak, osteomyelitis, or wound infection.

### **Authors**

**Patricia Sims Poole, MD and Dolores Pretorius, MD**  
**University of California San Diego**  
**San Diego, CA**

### **References**

1. Tsai EC, Santoreneos S, Rutka JT. Tumors of the Skull Base in Children: Review of Tumor Types and Management Strategies. *Neurosurgical Focus*. 2002 12(5).
2. Dahnert W. Radiology Review Manual, 6<sup>th</sup> Edition. Lippincott, Williams & Wilkins, 2007. 274-275.

3. Hoving EW. Nasal Encephaloceles. *Child's Nerv Syst.* 2000 16:702-706.
4. Gowda, D, Farrugia M, Padmanathan C. Case of the Month: An Intranasal Mass. *The British Journal of Radiology.* 2006 79:269-270.
5. Mahapatra AK, Suri A. Anterior Encephaloceles: A Study of 92 Cases. *Pediatr Neurosurg.* 2002 36:113-118.
6. Christoforidis GA, Baujan M, Bourekas EC. Case 3: Frontoethmoidal Encephalocele. *Am. J. Roentgenol.* 2000, 175: 893-894.