



**Society of Radiologists in Ultrasound  
2012 Toshiba Residents Program**

**Millicent Gentry, MD  
Mary Connell, MD  
Maricopa Medical Center  
Phoenix, AZ**

**Clinical History:**

A one-day old infant with a history of an abnormal antenatal ultrasound (US). Neonatal Head US.

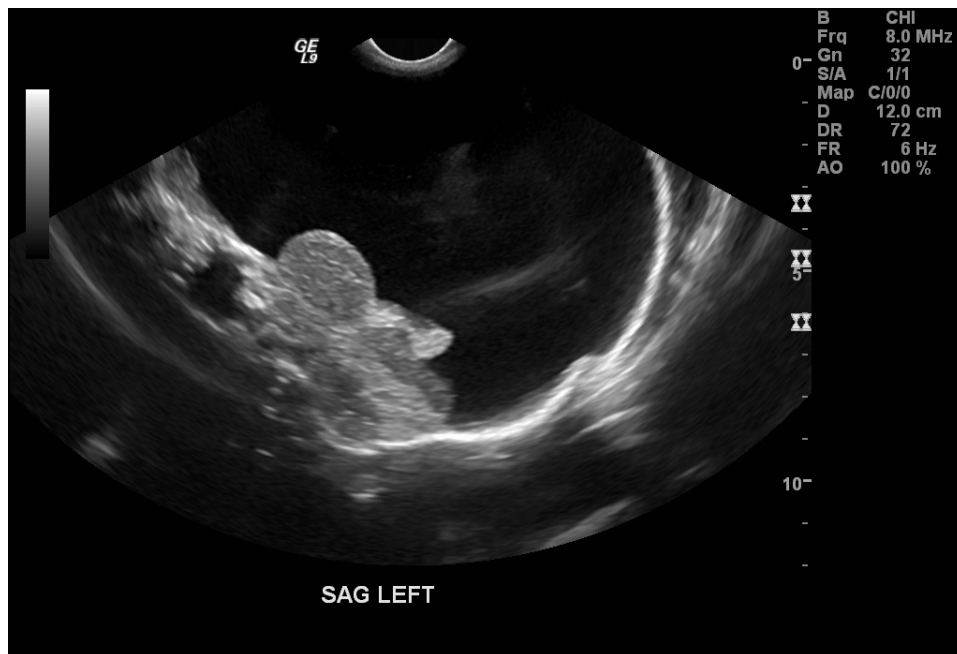


Figure 1

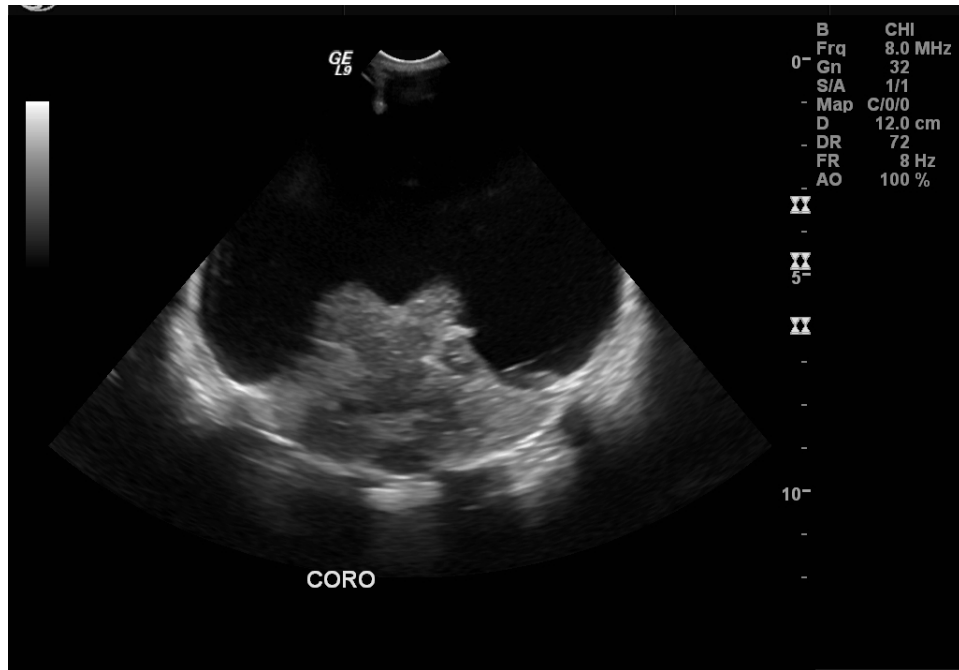


Figure 2

Non-contrast CT

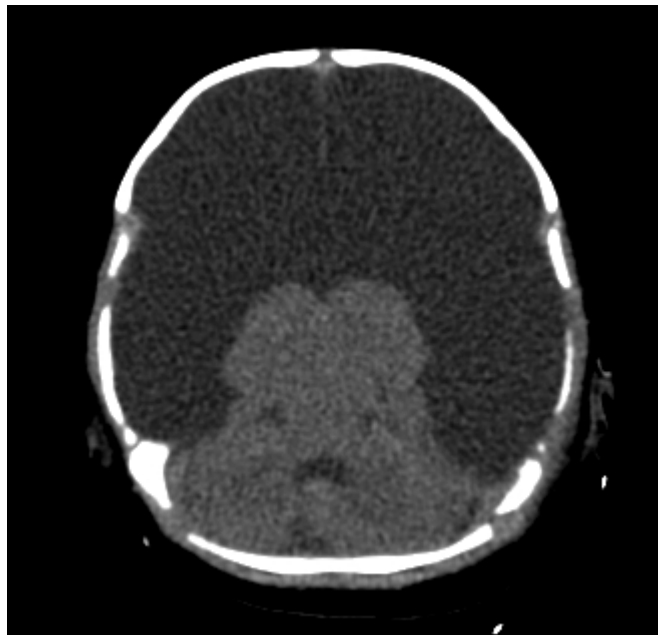


Figure 3

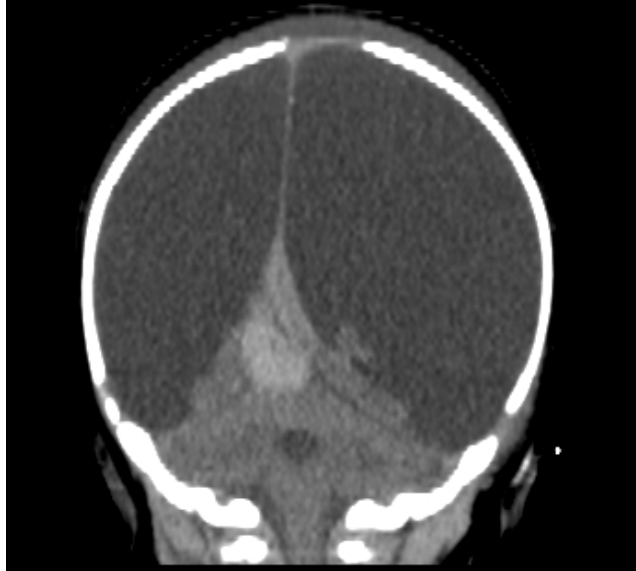

Figure 4

**Imaging Findings:**

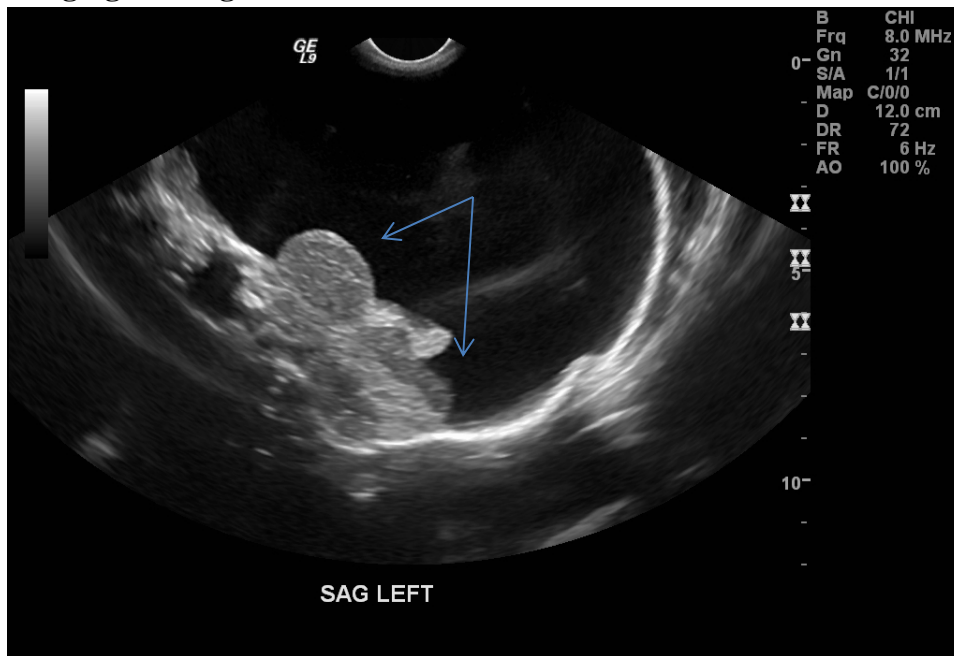


Figure 1: Parasagittal neonatal head US image shows absence of the cerebral hemispheres, which are replaced by a supratentorial fluid collection. Thalami and cerebellum (arrows) are intact.

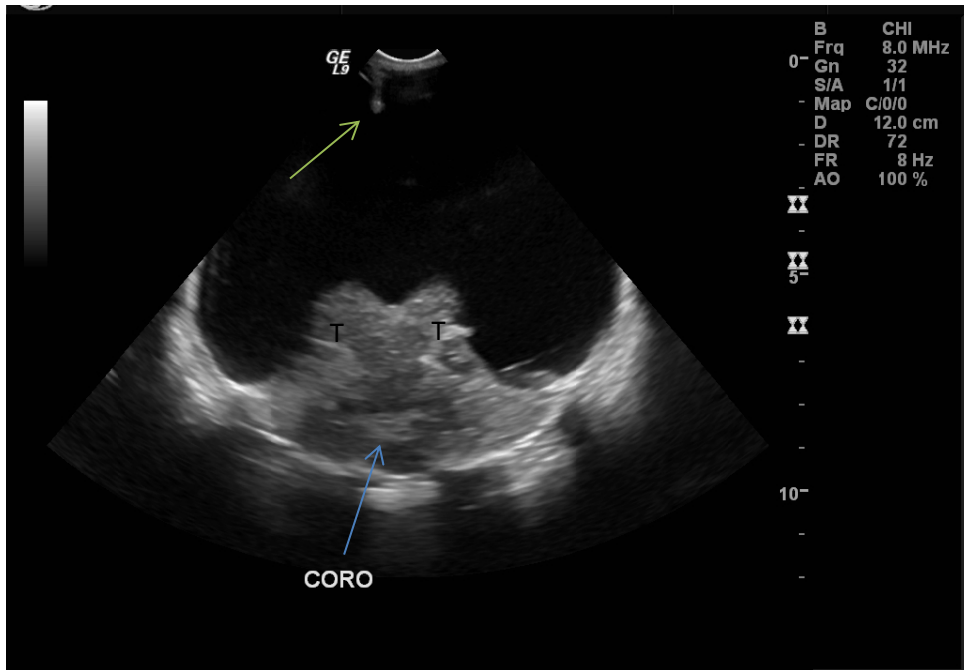


Figure 2: Coronal head US image shows absence of the cerebral hemispheres with preservation of the thalami (T) and cerebellum (blue arrow). Small portion of the falx (green arrow) is also seen.

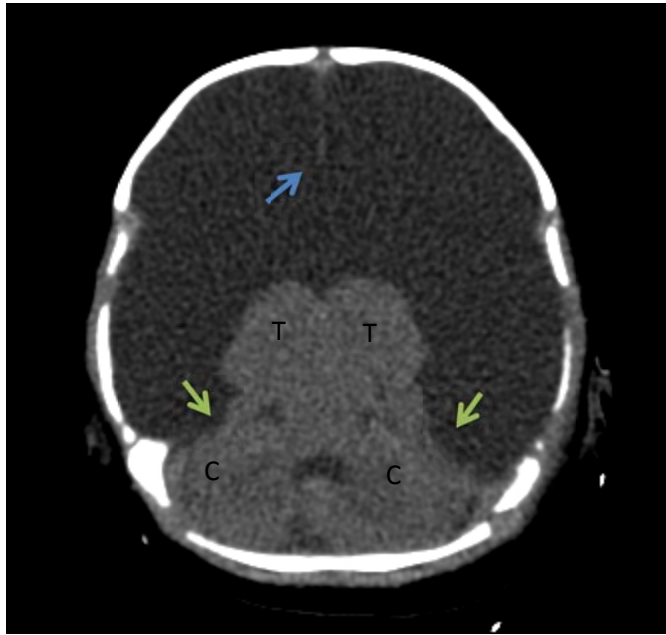


Figure 3: Axial NECT image shows replacement of most of the cerebral hemispheres by a supratentorial fluid collection. Islands of cerebral tissue are present in the temporal regions (green arrows). Thalami (T), cerebellar hemispheres (C), and falx (blue arrow) are intact.

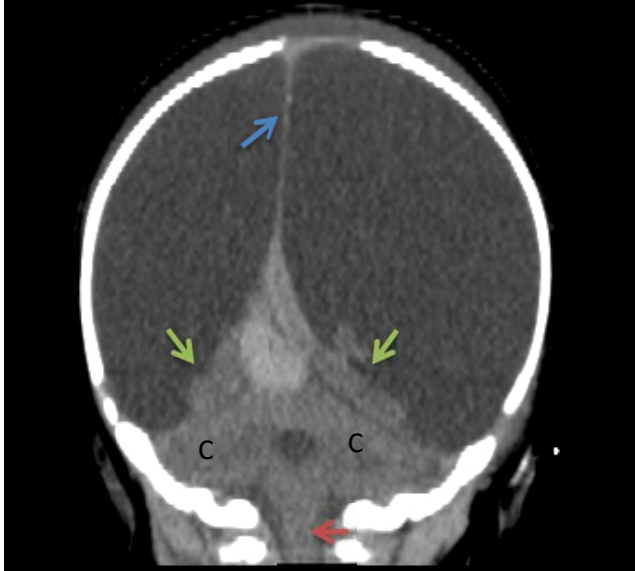


Figure 4: Coronal NECT image shows replacement of most of the cerebral hemispheres by a supratentorial fluid collection. Islands of cerebral tissue are present in the temporal regions (green arrows). Cerebellar hemisphere (C), brainstem (red arrow), and falx (blue arrow) are intact.

**Differential Diagnosis:**

Severe Hydrocephalus  
Alobar Holoprosencephaly  
Hydranencephaly

**Diagnosis:**

Hydranencephaly

**Discussion:**

Hydranencephaly is a central nervous disorder in which there is by replacement of the cerebral hemispheres by a thin membranous sac filled with cerebrospinal fluid and debris. It is a rare condition that occurs in approximately 1 per 100,000 births

The exact cause of hydranencephaly is not clear. However, five etiologies have been proposed:

1. Infarction: Occlusion of the supra-clinoid segments of the internal carotid arteries or of the middle cerebral arteries.
2. Leukomalacia: Extreme form of leukomalacia in which there is confluence of multiple cystic cavities.
3. Diffuse hypoxic-ischemic brain necrosis: Fetal hypoxia due to maternal exposure to carbon monoxide or butane gas resulting in massive tissue necrosis with cavitation and resorption of necrotized tissue.

4. Infection: Necrotizing vasculitis or local destruction of brain tissue secondary to intrauterine infection. Fetal infections associated with hydranencephaly include, congenital toxoplasmosis, cytomegalovirus, and herpes simplex infections (HSV).
5. Thromboplastic material from a deceased co-twin: Release of embolic or thromboplastic material from a deceased twin resulting in liquefaction of the brain tissue in the surviving twin.

Of the proposed etiologies of hydranencephaly listed above, the first is regarded by many to be the most likely, as animal studies have reproduced hydranencephaly in utero by carotid occlusion.

All imaging modalities, including US, CT, and MR, can be used to identify the features of hydranencephaly. In all cases, the imaging findings are essentially the same. The cerebral tissue supplied by the anterior circulation is absent. The thalami, brainstem, and cerebellum, which are supplied by the posterior circulation, are preserved. In many cases, islands of residual tissue are seen at the occipital poles and orbitofrontal regions. The falx is usually present, and the cranial cavity is filled with fluid.

Hydranencephaly is associated with a poor prognosis and the vast majority of affected infants do not survive beyond the first year of life.

**References:**

Barkovich AJ, Pediatric Neuroimaging, 3<sup>rd</sup> Edition, 2000, Lippincott, Williams and Wilkins, Philadelphia, page 158.

Dublin AB, et al. Diagnostic image evaluation of hydranencephaly and pictorially similar entities, with emphasis on computed tomography. Radiology. 137:81-91, 1980.

Greene MF, et al. Hydranencephaly: US appearance during in Utero Evolution. Radiology. 156: 779-780, 1985.

Kurtz AB, et al. Case 7: Hydranencephaly. Radiology. 210: 419-422, 1999.

Illner A. Hydranencephaly. Statdx. Web. 05 Oct. 2012. < <http://www.statdx.com>>

Poe LB, et al. Congenital central nervous system anomalies. Radiographics. 9(5):801-826, 1989.

Wheeler, TC, et al. Hydranencephaly. thefetus.net. Web. 05 Oct. 2012. <<http://www.sonoworld.com/fetus/page.aspx?id=116>>.

**Authors:**

**Millicent Gentry, MD**  
**Mary Connell, MD**  
**Maricopa Medical Center**  
**Phoenix, AZ**